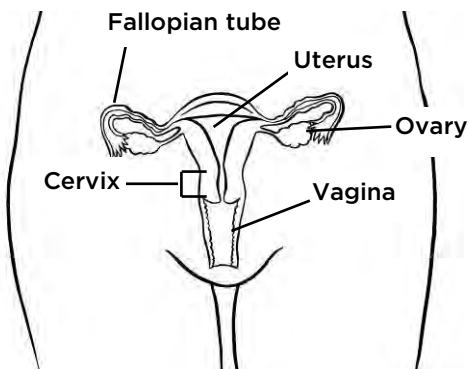
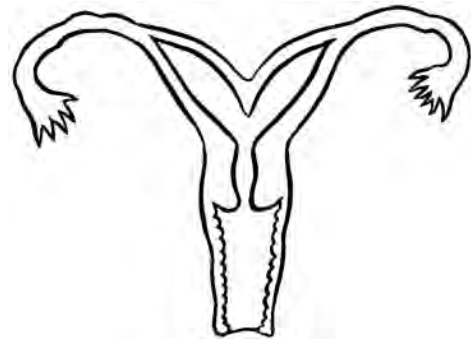


# Drawings of the Female Reproductive Organs

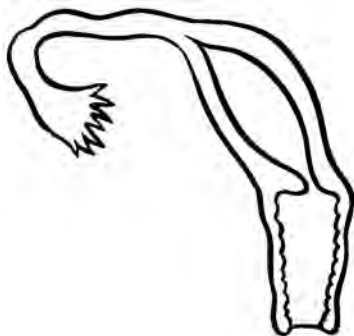
## Developmental (Congenital) Differences



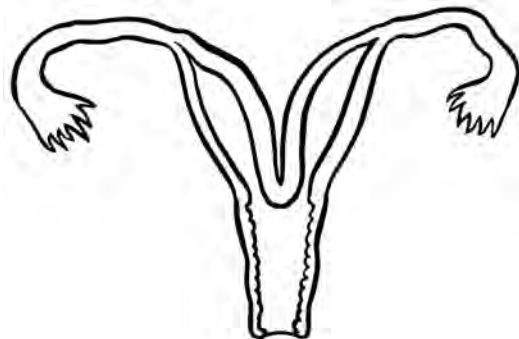
Normal Uterus



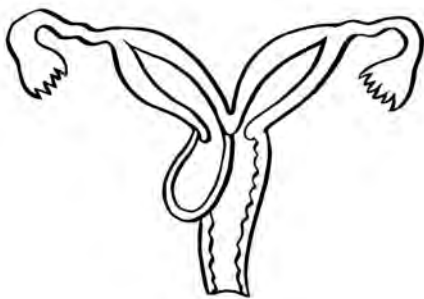
Bicornuate Uterus



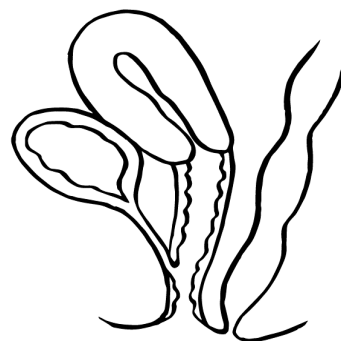
Unicornuate Uterus



Didelphys Uterus



OHVIRA



Urogenital Sinus

### To Learn More

- Adolescent Gynecology  
206-987-2028
- After hours on-call OB/GYN  
206-987-2000
- Ask your child's healthcare provider
- [seattlechildrens.org](http://seattlechildrens.org)

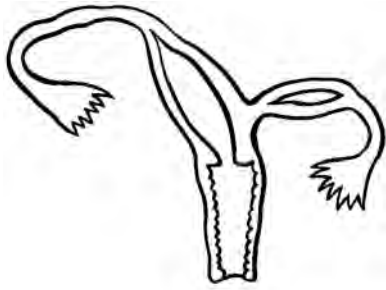
### Free Interpreter Services

- In the hospital, ask your nurse.
- From outside the hospital, call the toll-free Family Interpreting Line, 1-866-583-1527. Tell the interpreter the name or extension you need.

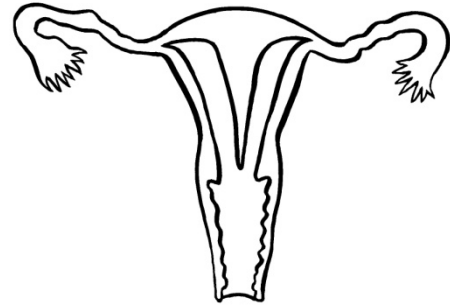


## Developmental Differences of the Female Reproductive Organs

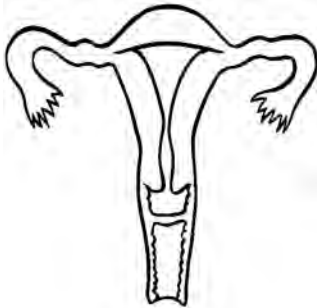
---



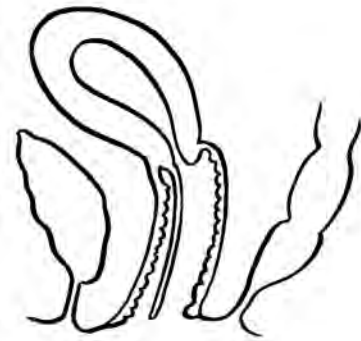Unicornuate uterus with non-communicating horn



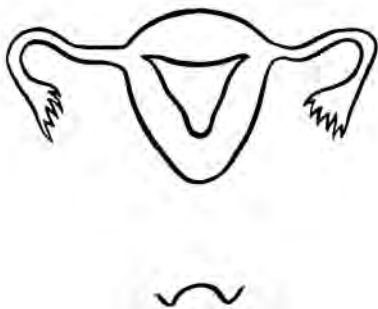
Uterine Septum



Transverse Vaginal Septum



Longitudinal Vaginal Septum




Vaginal Agenesis with Obstructed Uterus



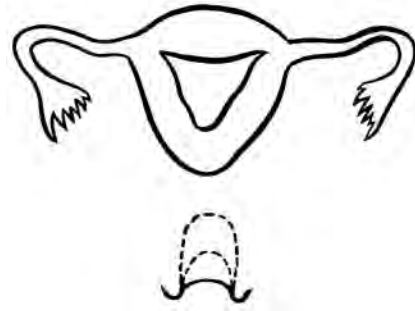
Vaginal Agenesis with obstructed uterus (side view)

## Developmental Differences of the Female Reproductive Organs

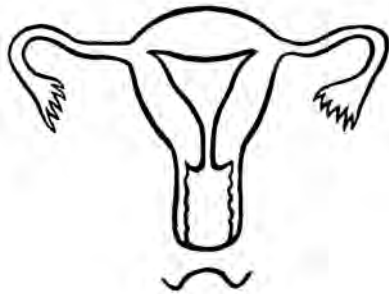
---



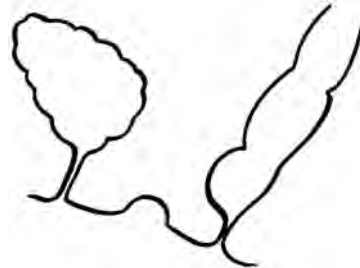
Unicornuate uterus with vaginal agenesis



Stretching the vagina with dilation



Distal vaginal agenesis



Vaginal agenesis without uterus